


NEW
PREVENTIVE USE



Eso-SPONGE®

ENDOLUMINAL VACUUM THERAPY FOR THE TREATMENT
AND PREVENTION OF ANASTOMOTIC LEAKAGES, AND FOR
THE TREATMENT OF PERFORATIONS, IN THE UPPER GI TRACT

Eso-SPONGE®


ENDOLUMINAL VACUUM THERAPY FOR THE TREATMENT OF ANASTOMOTIC LEAKAGES AND PERFORATIONS IN THE UPPER GI TRACT

Anastomotic leakages or other defects in the upper gastrointestinal tract can have serious consequences for the affected patients. Different parameters, like the size, location, time to diagnosis of the lesion, but also the general condition of the patient, have a significant influence on the clinical outcome of the patient. Often this situation is accompanied by symptoms of sepsis and a significant morbidity rate with corresponding substantial mortality rate. For this reason the treatment of this clinical situation is often a challenge for the clinician.

Besides surgical examination and the endoscopic stent system, good experiences have been obtained with the Endo-SPONGE® therapy for the lower gastrointestinal tract.

Now also the endoluminal vacuum therapy for the upper gastrointestinal is available – Eso-SPONGE®.





ANASTOMOTIC LEAKAGE IS A SEVERE COMPLICATION FOLLOWING GASTRIC AND ESOPHAGEAL SURGERY

Anastomotic leakage (AL):

- Is associated with high morbidity and mortality.¹⁻¹⁰
- Can occur after oesophageal surgery in up to 30% of cases.¹⁻¹⁰
- Can occur after gastric bypass and sleeve gastrectomy surgery in 1.5% and 4.9%.¹⁻¹⁰
- Has higher leak rate in cervical anastomosis (12.3% - 13.6%) than in thoracic anastomosis (2.9% - 9.3%).^{11, 12}
- Increases hospital costs.¹⁻¹⁰
- Increases length of stay.¹³
- Increases the reoperation risk.¹³
- Increases the risk of cancer recurrence.¹⁴
- Is related to worse long-term survival.¹³
- Increases the risk of stricture formation.¹³
- Delays oral feeding.¹³

ANASTOMOTIC LEAKAGE (AL) DIRECTLY AFFECTS THE MORTALITY RATE

- Mortality in patient with AL is reported to be between 2% - 35%.^{13, 15, 16}
- AL increases the mortality rate compared to no leakage.¹⁵
- Mortality is increased 2x in delayed AL diagnostic & treatment > 24h.¹⁶

Eso-SPONGE®

ENDOLUMINAL VACUUM THERAPY FOR THE TREATMENT OF ANASTOMOTIC LEAKAGES
AND PERFORATIONS IN THE UPPER GI TRACT



SUGGESTED BENEFITS OF VACUUM THERAPY ON THE TISSUE

- Increase blood flow and edema reduction.¹⁷
- Granulation tissue formation and extracellular synthesis.¹⁷
- Decrease of bacterial contamination and secretion.¹⁸

VACUUM THERAPY FOR THE UPPER GI

- Endoluminal Vacuum Therapy (EVT) is a feasible, safe and high efficient approach to treat anastomotic leaks and perforations within the upper GI.^{8-10, 19-38}
- EVT is used as the first method of choice for oesophageal leaks or perforations already in several hospitals.^{8, 10, 19-35}
- EVT has the potential to become the new standard of care for this indication.^{8, 10, 19-35}

Eso-SPONGE® TREATMENT SUGGESTED BENEFITS

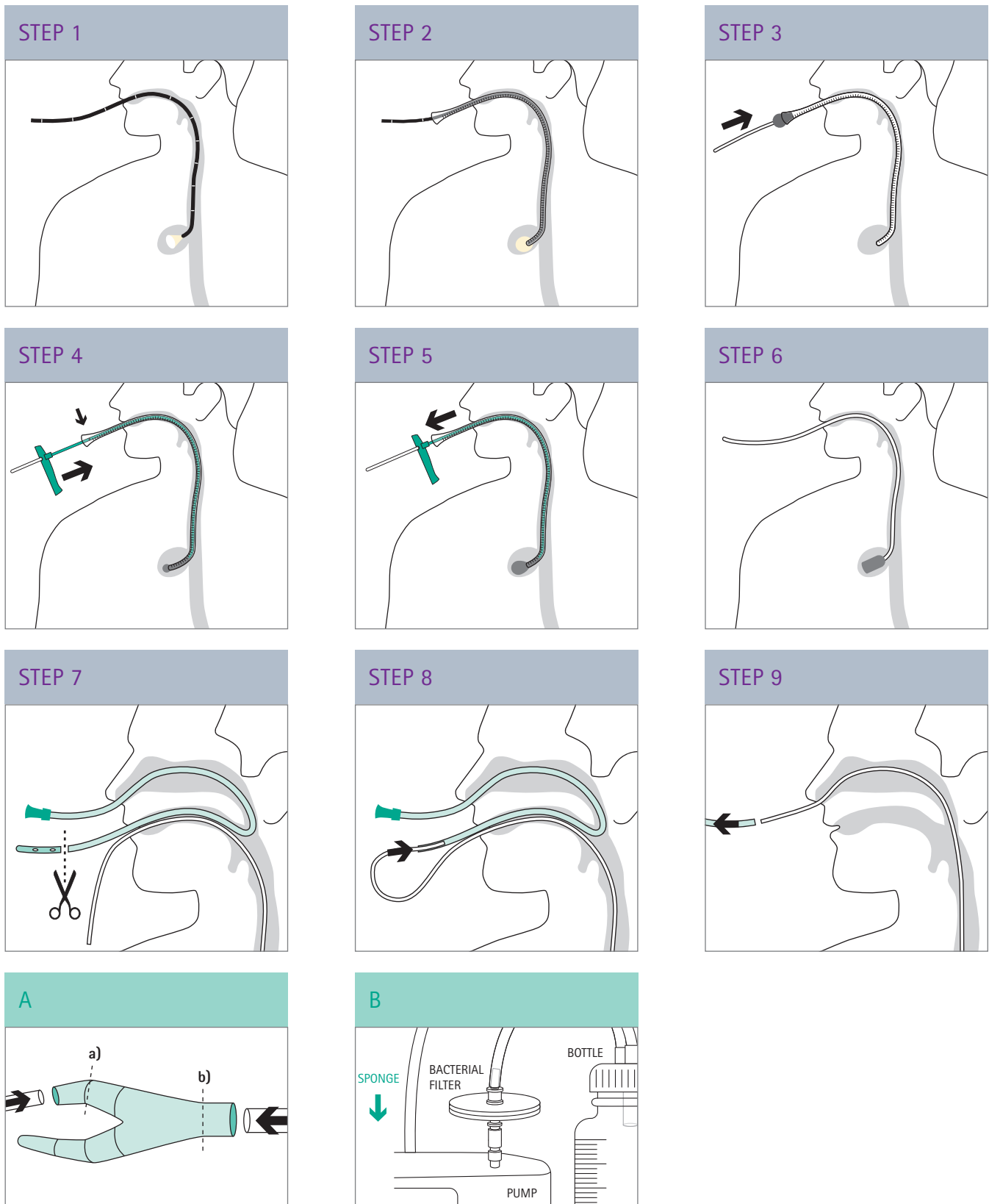
- The mean treatment duration time reported is less than 30 days.^{8, 9, 20, 24, 28, 29, 36-39}
- The average rate of successful treatment with Eso-SPONGE has been reported to occur in 84% of patients.*^{8, 9, 10, 24, 28, 29, 36-39}
- Early treatment is likely to achieve faster healing, shorter duration of treatment & hospital stay and less complications.^{5, 8-10, 24, 25, 28, 30, 36, 40}
- Continuous drainage, no secretion accumulation.^{8-10, 24, 28, 29, 36-38, 41-43}
- Infection control.^{8-10, 24, 28, 29, 36-38, 41-43}
- Debridement, quick cleaning of the wound cavity.^{8-10, 24, 28, 29, 36-38, 41-43}
- Promotion of granulation tissue ingrowth.^{8-10, 24, 28, 29, 36-38, 41-43}
- Mechanical reduction of the wound cavity.^{8-10, 24, 28, 29, 36-38, 41-43}
- Can be combined with enteral feeding.^{8, 24, 28, 36, 37, 39}
- If necessary, Eso-SPONGE can be combined with stent placement or operative revision for better control of the septic focus.^{8-10, 24, 44, 28, 29, 37, 38, 45}
- Contribute significantly to the reduction of morbidity and mortality of the patients.^{8-10, 19-37, 39, 41}
- Well tolerated with good short- and long-term clinical outcomes.^{8-10, 19-37, 39, 41}
- Likely to be superior to stent treatment and reduced need for surgical revision, and with less strictures.^{1, 10, 22, 23, 27-30}

* According to the product-related literature covered herein, wound closure or repair was achieved principally by Eso-SPONGE®, though some patients in some studies required additional stent therapy or surgical revision to ensure complete closure repair.

Eso-SPONGE®

ENDOLUMINAL VACUUM THERAPY FOR THE TREATMENT OF ANASTOMOTIC LEAKAGES AND PERFORATIONS IN THE UPPER GI TRACT

THERAPY PROCEDURE



TREATMENT CRITERIA

Eso-SPONGE® THERAPY PRINCIPLE

Treatment of anastomotic leaks or perforations in the upper gastrointestinal tract* by means of negative pressure including intraluminal or intracavitary therapy of paraoesophageal and mediastinal septic focus or localised abscesses endoscopically accessible.

*For use in the upper gastrointestinal tract understood as esophagus, stomach and duodenum, and endoscopically accessible within the range of the overtube length.

Eso-SPONGE® TREATMENT

Intraluminal and intracavitary therapy possible, see below instructions for intracavitary positioning of the Eso-SPONGE®.

STEP 1: The wound cavity should be measured (length and diameter) with an appropriate endoscope (leave the overtube at the distal part of the endoscope to be used in the next step). Cut the sponge slightly smaller than the cavity.

STEP 2: Push the overtube over the endoscope and introduce it under visual control using the endoscope as a guide until the tapered end is near the end of the cavity, leaving enough space for the sponge to deploy.

STEP 3: After leaving the overtube in the required position, place the drain of the sponge inside the pusher and introduce the sponge, previously impregnated with sterile hydrogel based on glycerol, through the overtube.

STEP 4: Push the Eso-SPONGE® to the mark with the pusher. The sponge is now at the end of the overtube (uncut sponge).

STEP 5: Advance gently until the sponge is expelled from the overtube, the resistance will fade once the sponge is released. Withdraw the overtube and pusher together.

STEP 6: The sponge will now expand in the leakage cavity. Check the position of the sponge using the endoscope to make sure that the sponge has not migrated and apply appropriate correction by means of endoscopic grasping forceps if necessary.

STEP 7: Transnasal channelling: Feed a 16 CH gastric tube in through the nose and out through the mouth. Cut off the atraumatic tip.

STEP 8: Connect the drain to the gastric tube in front of the mouth. Pull the stomach tube together with the drain back through the nose.

STEP 9: Disconnect the gastric tube. The drain is now transnasally channelled.*

* Remove of the sponge only through the mouth and never through the nose (!)

CONNECTION TO THE VACUUM SOURCE

How to use the variable speed medical vacuum pump MV 1 (MTG Sulzbach, Germany – distributed by B. Braun):

Fig. A:

- The redon drain must be introduced in the Y-connector to the minimum depth marked by dashed line.
- The connection of the secretion bottle must be introduced in the Y connector to the minimum depth marked by dashed line.

Fig. B: Connect the filter using a Luer Lock to the pump. Then attach the cylinder hose from the secretion bottle to the filter.

Suction is applied, if possible, under endoscopic inspection of the sponge at a negative pressure of 50 to 125 mmHg. Regular checking of the system is mandatory.

The system must be changed every 48-72 hours and, where appropriate, a new sponge inserted.

For more information look at the instructions for use.

Eso-SPONGE®

ENDOLUMINAL VACUUM THERAPY FOR THE TREATMENT OF ANASTOMOTIC LEAKAGES AND PERFORATIONS IN THE UPPER GI TRACT

MV1 VACUUM PUMP

- Pre-set at 125 mmHg
- Patient mobility thanks to battery
- Closed system
- 1000ml filling volume
- Alarm system



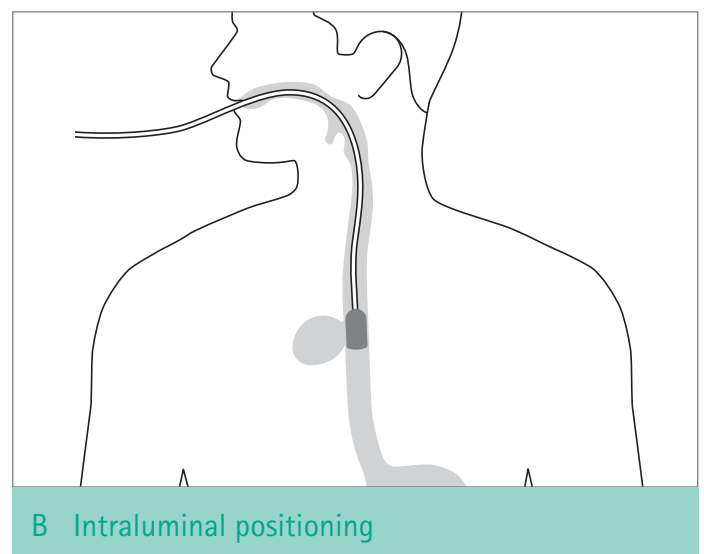
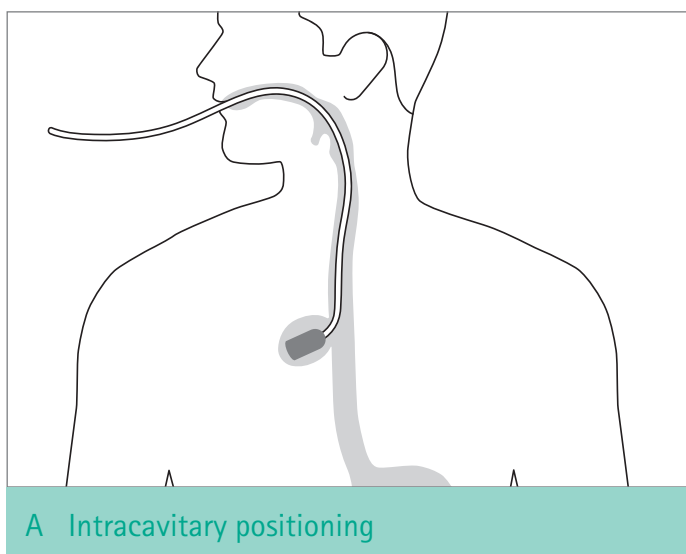
LITERATURE SUMMARY ON THE USE OF VACUUM THERAPY TO TREAT ANASTOMOSIS INSUFFICIENCY AND PERFORATIONS IN THE UPPER GI TRACT

YEAR	PAPER REFERENCE	N	INDICATION	TREATMENT DURATION (DAYS)	NUMBER OF SPONGE CHANGES	RATE OF HEALING	TYPE OF DEFECT (N)		
							AL	IP	O
2018	Bludau et al. ²⁸	77	Esophageal perforations and leakages from esophagogastrostomies	11 (1 - 65)	2.75 (1-9)	77.90%	59	18	0
2016	Kuehn et al. ⁸	21	Esophageal and gastric resections, esophageal perforation	15 (3-46)	5 (1-14)	90.5%	11	8	2
2020	Jung et al. ⁴⁸	30	Esophageal anastomotic leaks and perforations	16.1 (2-58)	AL=3.6 (1-13) IP=5.1 (1-12)	83.3%	23	7	0

AL: anastomotic leak, IP: iatrogenic perforation, O: other

RECOMMENDED PLACEMENT OF THE SPONGE

- Place the sponge preferentially in the cavity created by the leak or perforation: **Intracavitary positioning.**
- When intracavitary placement is challenging or not possible it is an option to place the sponge in the lumen in front of the defect: **Intraluminal positioning.**^{18, 34}




Eso-SPONGE®

ENDOLUMINAL VACUUM THERAPY FOR THE TREATMENT OF ANASTOMOTIC LEAKAGES AND PERFORATIONS IN THE UPPER GI TRACT

PRODUCT AND ORDERING INFORMATION

Eso-SPONGE®

- Overtube (2 sizes available)
- Pusher
- Irrigation set
- Y-shaped connector
- Slide clamp



NOT INCLUDED IN THE SET:

- Sterile hydrogel (glycerol based)
- Gastric tube CH 16
- Variable speed medical vacuum pump (see information about MV1 pump in this brochure)

ART.-NO.	NAME	DIAMETER OVERTUBE	CONTENT
5526550	Eso-SPONGE® 13 mm	Inner: 13 mm Outer: 17 mm	1 intervention set
5526540	Eso-SPONGE® 15 mm	Inner: 15 mm Outer: 19 mm	1 intervention set

Vacuum source (MV1, MTG Sulzbach)

ART.-NO.	NAME	CONTENT
MTG19116	MV1	1x Low vacuum pump
MTG18022	Bacterial filter	20 units
MTG18032	Collecting bottle	15 units

* This therapy requires the use of a standard or therapeutic gastroscope.

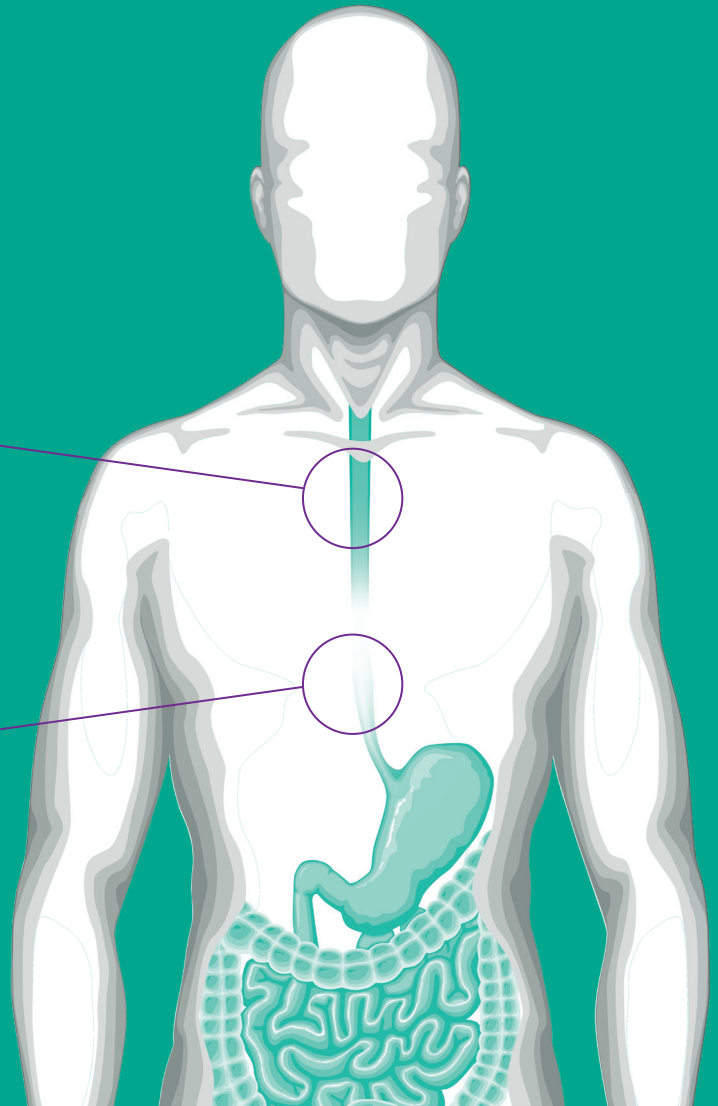
Eso-SPONGE®

NEW INDICATION: ENDOLUMINAL VACUUM THERAPY FOR PREVENTION OF ANASTOMOSTIC LEAKAGES IN THE UPPER GI TRACT

NEW PREVENTIVE USE

12.3% – 13.6%
LEAKAGE RATE IN CERVICAL ANASTOMOSIS^{11, 12}

2.9% – 9.3%
LEAKAGE RATE IN THORACIC ANASTOMOSIS^{11, 12}



1ST CHOICE IS ALWAYS PREVENTION!

Some patients have higher risk of developing an anastomotic leakage after esophagectomy due existing conditions such as:

- Calcification or arteries⁴⁶
- Heart failure, hypertension, renal insufficiency¹¹
- Obesity⁴⁷
- Diabetes¹¹

Now it is possible to use Eso-SPONGE® to reduce the risk of anastomotic leakages.

PILOT STUDY FOR PREEMPTIVE USE OF Eso-SPONGE® 24

Preemptive endoluminal vacuum therapy to reduce anastomotic leakage after esophagectomy: a game-changing approach?

Dis Esophagus. 2019 Jul 1;32(7)

Authors

C Gubler 1, D Vetter 2, H M Schmidt 2, P C Müller 2, B Morell 1, D Raptis 3, C A Gutschow 2

Affiliations

1 Department of Gastroenterology, and Transplant Surgery, University Hospital Zurich, Zurich, Switzerland.

2 Department of Visceral and Transplant Surgery, University Hospital Zurich, Zurich, Switzerland.

3 Department of HPB Surgery and Liver Transplantation, Royal Free London NHS Foundation Trust, London, United Kingdom.

Abstract

Endoluminal vacuum therapy (EVT) is an accepted treatment for anastomotic leakage (AL) after esophagectomy. A novel concept is to use this technology in a preemptive setting, with the aim to reduce the AL rate and postoperative morbidity. Preemptive EVT (pEVT) was performed intraoperatively in 19 consecutive patients undergoing minimally invasive esophagectomy, immediately after completion of esophagogastrostomy. Twelve patients (63%) were high-risk cases with severe comorbidity. The EVT device was removed routinely three to six (median 5) days after esophagectomy. The endpoints of this study were AL rate and postoperative morbidity. There were 20 anastomoses at risk in 19 patients. One patient (5.3%) experienced major morbidity (Clavien-Dindo grade IIIb) unrelated to anastomotic healing. He underwent open reanastomosis at postoperative day 12 with pEVT for redundancy of the gastric tube and failure of transition to oral diet. Mortality after 30 days was 0% and anastomotic healing was uneventful in 19/20 anastomoses (95%). One minor contained AL healed after a second course of EVT. Except early proximal dislodgement in one patient, there were no adverse events attributable to pEVT. The median comprehensive complication index 30 days after surgery was 20.9 (IQR 0-26.2). PEVT appears to be a safe procedure that may have the potential to improve surgical outcome in patients undergoing esophagectomy.

Keywords: anastomotic leakage; complications; minimally invasive esophagectomy; outcome research.

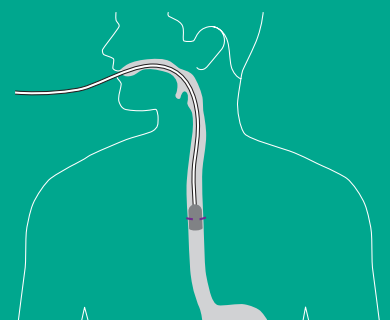
©The Author(s) 2018. Published by Oxford University Press on behalf of International Society for Diseases of the Esophagus.

RESULTS OF THE PILOT STUDY FOR PREEMPTIVE USE OF Eso-SPONGE®

- n=20 patients
- 1/20 leakage
- 20 patients had a sponge post surgery at the anastomotic site for 4-6 days.
- 19 patients recovered with no leakage.
- 1 patient develop a non symptomatic leak which was resolved with a second round of vacuum therapy.

PREVENTIVE USE OF Eso-SPONGE®

- Follow the insertion system as described for the treatment in steps 1 to 6 placing the end of the overtube at the anastomosis site.
- Release the Eso-SPONGE®, so that the sponge must be positioned at the anastomosis site.
- The drainage can be positioned transnasally (see steps 7 to 9).
- Connect the device to the vacuum source, low vacuum pump from MTG.
- Apply a continuous negative pressure of 75 mmHg as previously described.
- Leave the sponge for 4 to 6 days and retire the sponge.



Eso-SPONGE®

REFERENCES

- 1 Bemelman WA, Baron TH. Endoscopic Management of Transmural Defects, Including Leaks, Perforations, and Fistulae. *Gastroenterology*. 2018 May;154(7): p. 1938-46.e1.
- 2 Heits N, Egberts JH, Schniewind B, Hampe J, Becker T, Schafmayer C. Endoscopic-Vacuum-Therapy in Esophageous Perforations and Anastomotic Leakages after Esophagectomy. The Best Treatment Option to Solve a Major Complication in Upper GI-Surgery? *Ann Thorac Surg*. 2014 Mar;97(3):1029-35.
- 3 Holscher AH, Vallbohmer D, Brabende J. The prevention and management of perioperative complications. *Best Pract Res Clin Gastroenterol*. 2006;20(5):907-23.
- 4 Schaheen L, Blackmon SH, Nason KS. Optimal approach to the management of intrathoracic esophageal leak following esophagectomy: a systematic review. *Am J Surg*. 2014. 208(4): p. 536-43.
- 5 Sdralis EIK, Petousis S, Rashid F, Charalabopoulos A. Epidemiology, diagnosis, and management of esophageal perforations: systematic review. *Dis Esophagus*. 2017 Aug;30(8):1-6.
- 6 Di Leo M, Maselli R, Ferrara EC, Poliani L, Al Awadhi S, Repici A. Endoscopic Management of Benign Esophageal Ruptures and Leaks. *Curr Treat Options Gastroenterol*. 2017 Jun;15(2):268-84.
- 7 Blencowe NS, Strong S, McNair AG, Brookes ST, Crosby T, Griffin SM, Blazeby JM. Reporting of short-term clinical outcomes after esophagectomy: a systematic review. *Ann Surg*. 2012 Apr;255(4):658-66.
- 8 Kuehn F, Schiffmann L, Janisch F, Schwandner F, Alsfasser G, Gock M, Klar E. Surgical Endoscopic Vacuum Therapy for Defects of the Upper Gastrointestinal Tract. *J Gastrointest Surg*. 2016 Feb;20(2):237-43.
- 9 Heits N, Bernsmeier A, Reichert B, Hauser C, Hendricks A, Seifert D, Richter F, Schafmayer C, Ellrichmann M, Schniewind B, Hampe J, Becker T, Egberts JH. Long-term quality of life after endovac-therapy in anastomotic leakages after esophagectomy. *J Thorac Dis*. 2018 Jan;10(1):228-40.
- 10 Morell B, Murray F, Vetter D, Bueter M, Gubler C. Endoscopic vacuum therapy (EVT) for early infradiaphragmal leakage after bariatric surgery-outcomes of six consecutive cases in a single institution. *Langenbecks Arch Surg*. 2019 Feb;404(1):115-21.
- 11 Kassir ES, Kosinski AS, Ross P Jr, Koppes KE, Donahue JM, Daniel VC. Predictors of anastomotic leak after esophagectomy: an analysis of the society of thoracic surgeons general thoracic database. *Ann Thorac Surg*. 2013 Dec;96(6):1919-26.
- 12 Markar SR, Arya S, Karthikesalingam A, Hanna GB. Technical factors that affect anastomotic integrity following esophagectomy: systematic review and meta-analysis. *Ann Surg Oncol*. 2013 Dec;20(13):4274-81.
- 13 Grimminger PP, Goense L, Gockel I, Bergeat D, Bertheuil N, Chandramohan SM, Chen KN, Chon SH, Denis C, Goh KL, Gronnier C, Liu JF, Meunier B, Nafteux P, Pirchi ED, Schiesser M, Thieme R, Wu A, Wu PC, Buttar N, Chang AC. Diagnosis, assessment, and management of surgical complications following esophagectomy. *Ann N Y Acad Sci*. 2018 Dec;1434(1):254-73.
- 14 Bootsma BT, Huisman DE, Plat VD, Schoonmade LJ, Stens J, Hubens G, van der Peet DL, Daams F. Towards optimal intraoperative conditions in esophageal surgery: A review of literature for the prevention of esophageal anastomotic leakage. *Int J Surg*. 2018 Jun;54(Pt A):113-23.
- 15 Rutegård M, Lagergren P, Rouvelas I, Lagergren J. Intrathoracic anastomotic leakage and mortality after esophageal cancer resection: a population-based study. *Ann Surg Oncol*. 2012 Jan;19(1):99-103.
- 16 Persson S, Rouvelas I, Irino T, Lundell L. Outcomes following the main treatment options in patients with a leaking esophagus: a systematic literature review. *Dis Esophagus*. 2017 Dec 1;30(12):1-10.
- 17 Schintler MV. Negative pressure therapy: theory and practice. *Diabetes Metab Res Rev*. 2012 Feb;28 Suppl 1:72-7.
- 18 Kuehn F, Janisch F, Schwandner F, Alsfasser G, Schiffmann L, Gock M, Klar E. Endoscopic endoluminal vacuum therapy in Colorectal Surgery. *J Gastrointest Surg*. 2016 Feb;20(2):328-34.
- 19 Schniewind B, Schafmayer C, Voehrs G, Egberts J, von Schoenfels W, Rose T, Kurdow R, Arlt A, Ellrichmann M, Jürgensen C, Schreiber S, Becker T, Hampe J. Endoscopic endoluminal vacuum therapy is superior to other regimens in managing anastomotic leakage after esophagectomy: a comparative retrospective study. *Surg Endosc*. 2013 Oct;27(10):3883-90.
- 20 Smallwood NR, Fleshman JW, Leeds SG, Burdick JS. The use of endoluminal vacuum (E-Vac) therapy in the management of upper gastrointestinal leaks and perforations. *Surg Endosc*. 2016 Jun;30(6):2473-80.
- 21 Laukoetter MG, Mennigen R, Neumann PA, Dhayat S, Horst G, Palmes D, Senninger N, Vowinkel T. Successful closure of defects in the upper gastrointestinal tract by endoscopic vacuum therapy (EVT): a prospective cohort study. *Surg Endosc*. 2017 Jun;31(6):2687-96.
- 22 Brangewitz M, Voigtländer T, Helfritz FA, Lankisch TO, Winkler M, Klempnauer J, Manns MP, Schneider AS, Wedemeyer J. Endoscopic closure of esophageal intrathoracic leaks: stent versus endoscopic vacuum-assisted closure, a retrospective analysis. *Endoscopy*. 2013 Jun;45(6):433-8.
- 23 Mennigen R, Harting C, Lindner K, Vowinkel T, Rijcken E, Palmes D, Senninger N, Laukoetter MG. Comparison of Endoscopic Vacuum Therapy Versus Stent for Anastomotic Leak After Esophagectomy. *J Gastrointest Surg*. 2015 Jul;19(7):1229-35.
- 24 Gubler C, Vetter D, Schmidt HM, Müller PC, Morell B, Raptis D, Gutschow CA. Preemptive endoluminal vacuum therapy to reduce anastomotic leakage after esophagectomy: a game-changing approach? *Dis Esophagus*. 2019 Jul 1;32(7):doi126.
- 25 Neumann PA, Mennigen R, Palmes D, Senninger N, Vowinkel T, Laukoetter MG. Pre-emptive endoscopic vacuum therapy for treatment of anastomotic ischemia after esophageal resections. *Endoscopy*. 2017 May;49(5):498-503.
- 26 Möschler O, Nies C, Mueller MK. Endoscopic vacuum therapy for esophageal perforations and leakages. *Endosc Int Open*. 2015 Dec;3(6):E554-8.
- 27 Hwang JJ, Jeong YS, Park YS, Yoon H, Shin CM, Kim N, Lee DH. Comparison of Endoscopic Vacuum Therapy and Endoscopic Stent Implantation With Self-Expandable Metal Stent in Treating Postsurgical Gastroesophageal Leakage. *Medicine (Baltimore)*. 2016 Apr;95(16):e3416.
- 28 Bludau M, Fuchs HF, Herbold T, Maus MKH, Alakus H, Popp F, Leers JM, Bruns CJ, Hölscher AH, Schröder W, Chon SH. Results of endoscopic vacuum-assisted closure device for treatment of upper GI leaks. *Surg Endosc*. 2018 Apr;32(4):1906-14.

- 29 Valli PV, Mertens JC, Kröger A, Gubler C, Gutschow C, Schneider PM, Bauerfeind P. Stent-over-sponge (SOS): a novel technique complementing endosponge therapy for foregut leaks and perforations. *Endoscopy*. 2018 Feb;50(2):148-53.
- 30 Rausa E, Asti E, Aiolfi A, Bianco F, Bonitta G, Bonavina L. Comparison of endoscopic vacuum therapy versus endoscopic stenting for esophageal leaks: systematic review and meta-analysis. *Dis Esophagus*. 2018 Nov 1;31(11).
- 31 Pournaras DJ, Hardwick RH, Safranek PM, Sujendran V, Bennett J, Macaulay GD, Hindmarsh A. Endoluminal Vacuum Therapy (E-Vac): A Treatment Option in Oesophagogastric Surgery. *World J Surg*. 2018 Aug;42(8):2507-11.
- 32 Heits N, Stapel L, Reichert B, Schafmayer C, Schniewind B, Becker T, Hampe J, Egberts JH. Endoscopic endoluminal vacuum therapy in esophageal perforation. *Ann Thorac Surg*. 2014 Mar;97(3):1029-35.
- 33 Weidenhagen R, Hartl WH, Gruetzner KU, Eichhorn ME, Spelsberg F, Jauch KW. Anastomotic leakage after esophageal resection: new treatment options by endoluminal vacuum therapy. *Ann Thorac Surg*. 2010 Nov;90(5):1674-81.
- 34 Loske G, Schorsch T, Dahm C, Martens E, Müller C. Iatrogenic perforation of esophagus successfully treated with Endoscopic Vacuum Therapy (EVT). *Endosc Int Open*. 2015 Dec;3(6):E547-51.
- 35 Ooi G, Burton P, Packiyathan A, Loh D, Chen R, Shaw K, Brown W, Nottle P. Indications and efficacy of endoscopic vacuum-assisted closure therapy for upper gastrointestinal perforations. *ANZ J Surg*. 2018 Apr;88(4):E257-63.
- 36 Alakkari A, Sood R, Everett SM, Rembacken BJ, Hayden J, Sarela A, Mohammed N. First UK experience of endoscopic vacuum therapy for the management of oesophageal perforations and postoperative leaks. *Frontline Gastroenterol*. 2019 Apr;10(2):200-203.
- 37 Chon SH, Toex U, Plum PS, Fuchs C, Kleinert R, Bruns C, Goeser T. Successful closure of a gastropulmonary fistula after esophagectomy using the Apollo Overstitch and endoscopic vacuum therapy. *Endoscopy*. 2018 Jul;50(7):E149-50.
- 38 Herbold T, Chon SH, Grimminger P, Maus MKH, Schmidt H, Fuchs H, Brinkmann S, Bludau M, Gutschow C, Schröder W, Hölscher AH, Leers JM. Endoscopic Treatment of Transesophageal Echocardiography-Induced Esophageal Perforation. *J Laparoendosc Adv Surg Tech A*. 2018 Apr;28(4):422-28.
- 39 Glatz T, Fischer A, Hoepfner J, Thimme R, Walker C, Richter-Schrag HJ. Vacuum sponge therapy using the pull-through technique via a percutaneous endoscopic gastrostomy to treat iatrogenic duodenal perforation. *Endoscopy*. 2015;47 Suppl 1:E567-8.
- 40 Verlaan T, Voermans RP, van Berge Henegouwen MI, Bemelman WA, Fockens P. Endoscopic closure of acute perforations of the GI tract: a systematic review of the literature. *Gastrointest Endosc*. 2015 Oct;82(4):618-28.e5.
- 41 Loske G. Endoscopic negative pressure therapy of the upper gastrointestinal tract. *Chirurg*. 2019 Jan;90 (Suppl 1):1-6.
- 42 Loske G, Müller CT. Tips and tricks for endoscopic negative pressure therapy. *Chirurg*. 2019 Jan;90:(Suppl 1):7-17.
- 43 Comellas E, Bellomo FJ, Rosales I, Del Castillo LF, Sánchez R, Turón P, Oller S. On the feasibility of the computational modelling of the endoluminal vacuum-assisted closure of an oesophageal anastomotic leakage. *R Soc Open Sci*. 2018 Feb 7;5(2):171289.
- 44 Bludau M, Hölscher AH, Herbold T, Leers JM, Gutschow C, Fuchs H, Schröder W. Management of upper intestinal leaks using an endoscopic vacuum-assisted closure system (E-VAC). *Surg Endosc*. 2014 Mar;28(3):896-901.
- 45 Kuehn F, Schiffmann L, Rau BM, Klar E. Surgical endoscopic vacuum therapy for anastomotic leakage and perforation of the upper gastrointestinal tract. *J Gastrointest Surg*. 2012 Nov;16(11):2145-50.
- 46 van Rossum PSN, Jeene PM, Rozema T, Braam PM, Lips IM, Muller K, van Kampen D, Vermeulen BD, Homs MYV, Oppedijk V, Berbée M, C C M Hulshof M, Siersema PD, El Sharouni SY. Patient-reported outcomes after external beam radiotherapy versus brachytherapy for palliation of dysphagia in esophageal cancer: a matched comparison of two prospective trials. *Radiother Oncol*. 2020 Oct 13:S0167-8140(20)30845-8.
- 47 Zhang SS, Yang H, Luo KJ, Huang QY, Chen JY, Yang F, Cai XL, Xie X, Liu QW, Bella AE, Hu RG, Wen J, Hu Y, Fu JH. The impact of body mass index on complication and survival in resected oesophageal cancer: a clinical-based cohort and meta-analysis. *Br J Cancer*. 2013 Nov 26;109(11):2894-903.
- 48 Jung C, F, M, Müller-Dornieden A, Gaedcke J, Kunsch S, Gromski M, A, Biggemann L, Seif Amir Hosseini A, Ghadimi M, Ellenrieder V, Wedi E: Impact of Endoscopic Vacuum Therapy with Low Negative Pressure for Esophageal Perforations and Postoperative Anastomotic Esophageal Leaks. *Digestion* 2020. doi: 10.1159/000506101

AESCULAP® – a B. Braun brand

Aesculap AG | Am Aesculap-Platz | 78532 Tuttlingen | Germany
Phone +49 7461 95-0 | Fax +49 7461 95-2600 | www.aesculap.com

Manufacturer

Endo-SPONGE, Eso-SPONGE:
B. Braun Surgical, S.A. | Carretera de Terrassa, 121 | 08191 Rubí | Spain

Vacuum source manufactured by:
MTG Medizinische-Technische Gerätebau GmbH | Zur Seilscheibe 10, 66280 Sulzbach/Saar | Germany

The main product trademark "AESCULAP" and the product trademarks "Endo-SPONGE" and "Eso-SPONGE" are registered trademarks of Aesculap AG.

Subject to technical changes. All rights reserved. This brochure may only be used for the exclusive purpose of obtaining information about our products. Reproduction in any form partial or otherwise is not permitted.